



Femoroacetabular impingement after the femoral neck fracture healed in a nonanatomical position

Femoroacetabularni impingement usled neanatomskog zarastanja kod preloma vrata butne kosti

Marko Mladenović*, Ivan Micić*†, Saša Milenković*†, Predrag Stojiljković*, Radoslav Barjaktarović‡

Clinical Center Niš, *Clinic for Orthopaedics Surgery, and Traumatology, Niš, Serbia; University of Niš, †Faculty of Medicine, Niš, Serbia; Military Medical Academy, ‡Clinic for Orthopaedic Surgery and Traumatology, Belgrade, Serbia

Abstract

Introduction. Femoroacetabular impingement is the result of the pathological conditions in the osseous acetabulum and/or the proximal femur. One of its causes is a non-anatomically healed femoral neck fracture. **Case report.** A male, aged 51, with a subcapital left femoral neck fracture was treated conservatively. The fracture healed 9 months later and although the patient was walking on crutches he suffered from pain in the left groin. The X-ray images showed the valgus and the retroposition of the left femoral head. The patient was operated on and intraoperatively the thickness and a bone prominence in the anterosuperior femoral neck area in the line of the previous fracture were found, which was pressing and spreading beneath the acetabular *labrum*, thus squeezing the acetabular cartilage. The *labrum* lesion which was found was the result of the mechanical pressure of the existing femoral neck deformity during the hip movements. Irretrievably damaged part of the *labrum* was resected and the anterosuperior femoral head-neck osteochondroplasty was done. One year after the surgery, the patient had no pain, he walked without limping, the impingement test was negative, the radiological parameters were adjusted and there were no signs of the avascular necrosis of the femoral head. **Conclusion.** The femoral neck fracture should be treated adequately with the full anatomical position and the proper internal fixation. If the deformity occurs as the result of a treatment, it should be removed as soon as possible to prevent the osteoarthritis of the hip.

Key words:

hip fractures; pain; femoroacetabular impingement; hip joint; orthopedic procedures; treatment outcome.

Apstrakt

Uvod. Femoroacetabularni poremećaj je rezultat patoloških stanja u acetabulumu i/ili proksimalnom femuru. Jedan od njegovih uzroka je i ne-anatomski zarastao prelom vrata femura. **Prikaz bolesnika.** Muškarac, star 51 godinu, sa subkapitalnim prelomom vrata leve butne kosti, lečen je konzervativno. Prelom je zarastao tek devet meseci kasnije. Pacijent je hodao na štakama i patio od bolova u predelu levog zgloba kuka. Rendgenske slike pokazale su valgus i retropoziciju leve femoralne glave. Pacijent je bio operisan i intraoperativno je nađeno zadebljanje u anterosuperiornom delu vrata butne kosti u nivou linije prethodne frakture. Ovo zadebljanje vršilo je pritisak i destrukciju acetabularne hrskavice i labruma. Lezija labruma koja je bila pronađena, bila je rezultat mehaničkog pritiska postojećeg deformiteta vratnog dela femura tokom kretanja kuka. Nepovratno oštećeni deo labrum-a je reseciran i urađena je osteochondroplastika anterosuperiorne femoralne glave i vrata. Godinu dana nakon operacije, pacijent je bio bez bolova, hodao je bez hramanja, a impingement test bio je negativan. Radiološki parametri bili su popravljani i nije bilo znakova avaskularne nekroze femoralne glave. **Zaključak.** Frakturu vrata butne kosti treba adekvatno lečiti punom anatomskom repozicijom i pravilnom unutrašnjom fiksacijom. Ako se deformacija javlja kao rezultat lečenja, treba je ukloniti što je pre moguće kako bi se sprečio osteoartritis kuka.

Ključne reči:

kuk, prelomi; bol; femoroacetabularni sudar; kuk, zglob; ortopedске procedure; lečenje, ishod.

Introduction

Femoroacetabular impingement (FAI) is the cause of the hip pain in young adults and is a potential cause of a hip

arthrosis development¹⁻⁹. The minimal bone changes of the proximal femur and/or acetabulum combined with FAI as a pathophysiological mechanism, lead to an early *labrum* lesion and adjacent cartilage. FAI represents a marginal con-

flict of the altered bone morphology between the rim of the acetabulum and the proximal femur of the hips^{10,11}. Flexion, internal rotation and the adduction of the hip provokes the unnatural contact between the femoral head-neck junction in the aspect of the asphericity with the anterosuperior upper rim of the acetabulum.

Two basic mechanisms of FAI have been described: cam impingement and pincer impingement, with a mixed type which combines the previous two. The cam impingement appears in younger, more often male adults and is the result of morphological, bone changes at the proximal femur, at the femoral head-neck junction in the form of a bone thickening or a cam, with the aspherical configuration of this junction. These changes, depending on the author who described it, were called "pistol grip"¹² or "tilt" deformity of the proximal femur⁵. Such changes can be seen in, slipped capital femoral epiphysis¹³⁻¹⁵, Legg-Calve-Perthes disease^{16,17}, avascular necrosis of the femoral head¹⁸ and non-anatomically healed femoral neck fractures^{19,20}.

During the flexion, the adduction and the internal rotation in the hip, anterosuperior, pathologically altered part of the femoral head-neck junction, spreads beneath the acetabular *labrum*, thus squeezing the *labrum* adjacent articular cartilage, while the *labrum* itself, initially, remains intact. Consequently separation of the acetabular cartilage from the *labrum* and subchondral bone occurs. Acetabular cartilage is irretrievably damaged, separating from the subchondral bone and the adjacent *labrum*, which leads to the degenerative changes of the hip^{1,21,22}. Due to the fact that the *labrum* lesion occurs last, and the *labrum* is richly innervated, the groin pain intensifies in the developed stages of the disease appears²³ which is the reason why the cam FAI is malignant morfotype of the disease.

We presented a relatively rare form of a cam FAI, which is the result of a non-anatomically healed femoral neck fracture and also the results of the surgical treatment of the hip changes induced by trauma.

Case report

A male, aged 51, was hurt in July, 2009. Radiological finding was as follows: subcapital left femoral neck fracture with the dislocation of the femoral head in abduction. The patient was treated conservatively. The patient complained of a severe and constant pain in the left groin, the after conservative treatment was completed, he could not walk without crutches and he was limping when walking. Nine months after the injury, physical examination of the patient confirmed limping on the left leg, slightly positive Trendelenburg's sign on the left leg and the limited motion in the hip joint: flexion up to 80°, internal rotation 20°, external rotation 45°, abduction is 40° and adduction up to 10°. The impingement test¹ was positive in the range of 40–80° of the flexion. The clinical findings were graded according to the Western Ontario and McMaster Universities Osteoarthritis Index (WOMAC)²⁴, and it was 76.

Radiological findings showed the healed subcapital femoral neck fracture without necrosis of the femoral head.

The anteroposterior (AP) X-ray images of the hips (Figure 1) showed the value of collocal capital diaphyseal angles (CCD) at the healthy right hip of 135° and at the injured, left hip 149° that was in favour of healing the femoral neck in abduction, i.e., *valgus* position of 19°²⁵. Tonnis angle²⁶, had the value of 0° on both sides, the value of Wiberg angle²⁷, on the right hip was 43°, and on the injured, left hip, it was 38°. The value of the alpha angle, as the parameter of the femoral head convexity, as seen on the AP X-ray images of the hips, measured by the Nötzly method²⁸, on the right hip was 47°, and on the left hip was 57°. On the Dunn-Rippstein Müller lateral X-ray images, on the right hip, the alfa angle was 40° and on the left hip 73°, with the evident retroposition of the femoral head on the injured hip in relation to the healthy hip, with the disparity of 33° (Figure 2). The head of the femoral bone is not located centrally on the femoral neck, but it is located back and upwards. We measured the angle between the head of the femoral bone and its neck – the gama angle or collocal capital angle²⁵. Its normal value is $-1^\circ < \text{gama} < 2^\circ$; in our patient the gama angle was 5° (Figures 3 and 4).

The open surgical procedure, so-called trochanteric major flip osteotomy approach^{29,30}, was performed in May 2010 under spinal anesthesia, 9 months after the hip injury. After the anterior "Z" capsulotomy, the controlled anterior surgical dislocation of the hip was performed.

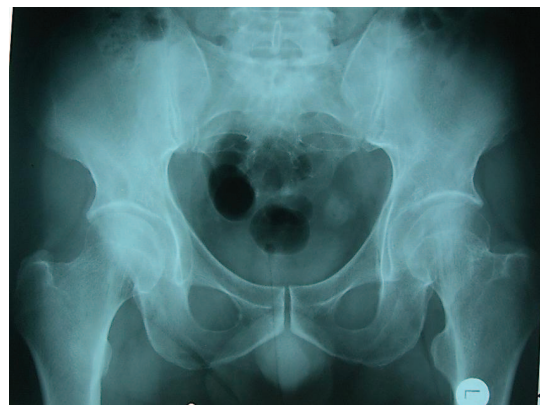

Fig. 1 – Standardized anteroposterior radiographic image of the hips. Left: femoral bone neck fracture healed in abduction.

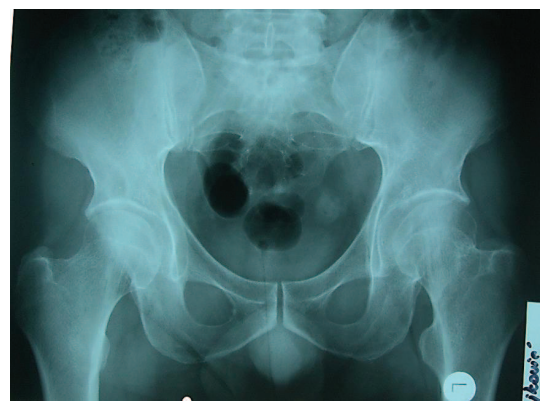


Fig. 2 – Standardized Dunn-Rippstein-Müller radiographic image of the hips. Left hip: femoral bone neck fracture healed in retroposition of the femoral head.

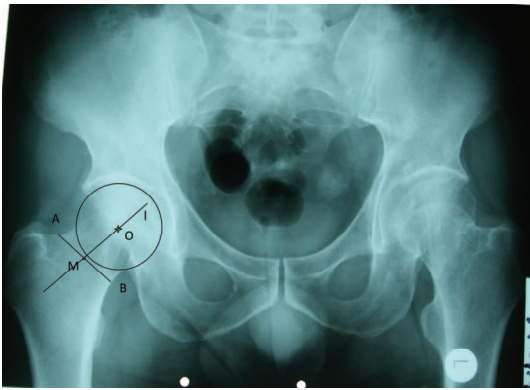


Fig. 3 – Femoral head axis (1) – AB, the line that connects upper and lower edge of the femoral bone neck on anteroposterior (AP) radiographic images of the hip, and front and rear edge of the neck on Dunn90°. M, the central point of the AB line. O, the center of femoral head rotation. OM is a line that represents the axis of femoral bone neck (axis 1) – it depends on the position of the femoral bone head center.

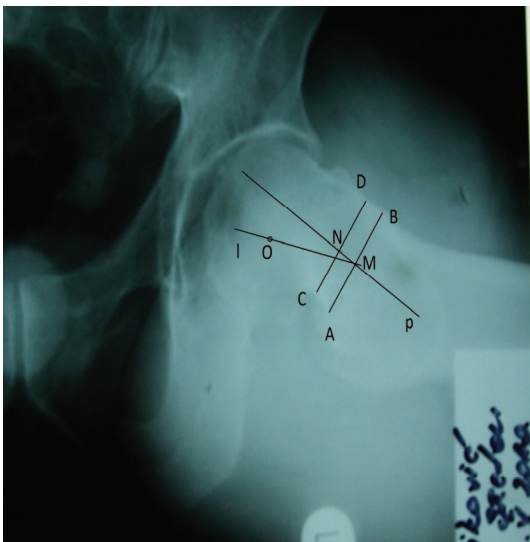


Fig. 4 – Femoral head axis represented by two parallel lines (p) – AB, the line drawn on the narrowest part of the femoral bone neck. CD, the line drawn 3–4 mm medially from the line AB. M, the central point of the AB line. N, the central point of the CD line. MN, the line that represents the axis of the medial third of the femoral bone neck, the position of which does not depend on the center of femoral head rotation. Axes l and p overlap ($l = p$) when the head of the femur is located centrally on the neck. Gama angle is collo-capital angle of the femoral head created by l and p axes, the basic value in the pilot study of healthy hips is $-1^\circ < \text{gama} < 2^\circ$. In the case of our patient the angle gama is 5° .

Intraoperatively, in the anterosuperior femoral neck region, the femoral neck bone prominence in the shape of a cam was noticed (Figure 5). This prominence, i.e., cam, was osteotomized, taking into consideration that the size of the resection of the neck does not exceed 30% of its thickness^{31–}

³³ (Figure 6). A resection osteoplasty of the impinging site on the neck-head junction was performed to improve femoroacetabular offset. In the upper anterosuperior part of the acetabulum, ranging from 12–17 hours^{4, 34}, the separation and serious damage of the *labrum* from its ledge was noticed. With no possibility of its refixation, the partial resection of the *labrum* was conducted. The reposition of the hip was performed, the joint capsule reconstructed and a major trochanter was fixed.

On the first postoperative day, active exercises in bed started and walking on the crutches was allowed from the second day with a touch down on the tip toes of the operated leg for 6 weeks after the surgery.

One year after the surgery, we found: the absence of the hip pain, walking without crutches and no limping, Trendelenburg sign negative, the impingement test also negative, the hip flexion was 90° , the internal rotation 15° and the other movements of the hip were within the normal range, and WOMAC score was 94.

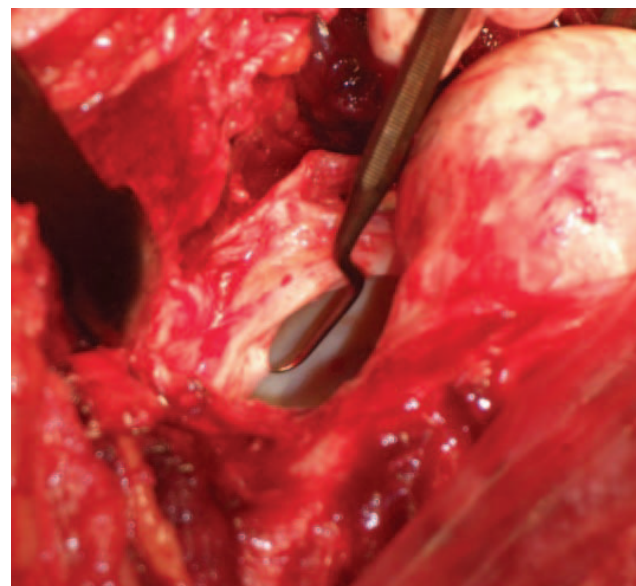
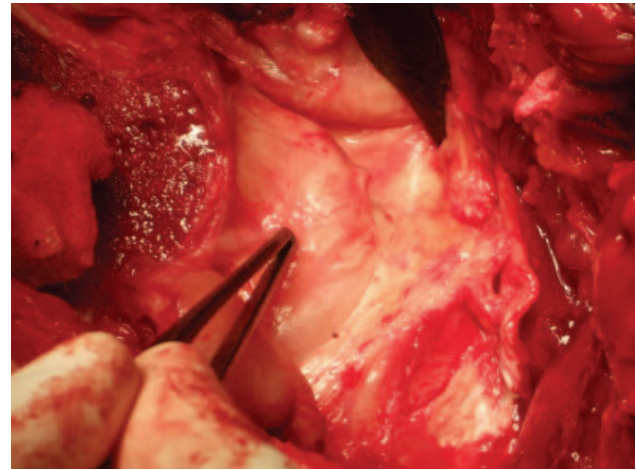


Fig. 5 – Intraoperative images: up – the cam deformity of femoral head and neck juncture impacts acetabular labrum; down – elevated and damaged acetabular labrum.

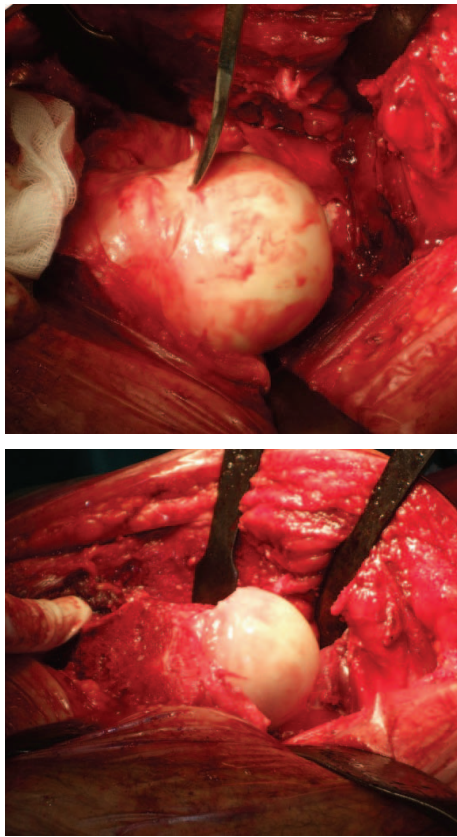


Fig. 6 – Intraoperative images: up – osteochondroplastica of the cam deformity of femoral head and neck juncture; down – the corrected cam deformity on the front side of head and neck of the femoral bone.

Postoperative Dunn-Rippstein-Müller profile X-rays images of the hip showed the reduction of the alpha angle values of the injured hip, from 73° to 50° , while on the AP X-rays the value of alpha angle was reduced from 57° to 52° , and the value of gamma angle was reduced from 5° to 1° (Figure 7). Trochanter osteotomy of the femur, was healed, the femoral head was clearly contoured, without bone cysts and with no signs of the avascular necrosis development et heterotopic ossification.

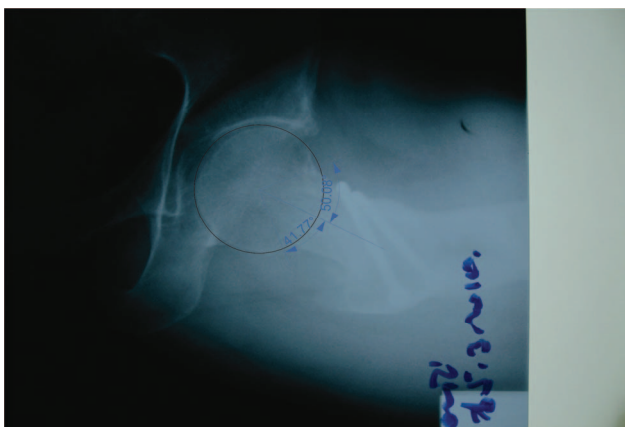


Fig. 7 – Postoperative Dunn-Rippstein-Müller radiographic image of the hip.

Discussion

There are few papers in the literature dealing with surgical correction of the deformity at the femoral head-neck junction after femoral neck fractures healed in a nonanatomical position^{16,17}. Thus Eijer et al.¹⁹ in their paper, presented the treatment of 9 patients using the open surgical method, whereas all the other authors^{3,8,13,25,27} presented in their papers the surgical treatment of the non-traumatic cam FAI form in patients with the pathological substrate at the femoral head-neck junction.

Dislocated fractures of the femoral neck, as a routine, are treated by the partial or the total hip replacement, and, in younger adults, the open reduction and internal fixation of the neck fracture are recommended. Only a few patients, with nondislocated femoral neck fractures are treated conservatively. In this presented case, dislocation of the femoral head in relation to the femoral neck was not noticed, and the treatment was conservatively completed. The patient's persistent symptoms and the subsequent clinical and radiographic examinations showed the presence of the bone prominence, i.e., cam in the anterosuperior region of the femoral neck in the area of the former fracture which led to the conclusion that it was very rare, trauma provoked form of the femoroacetabular impingement. The cam deformity is a consequence of osteogenesis on the place of femoral neck fracture. The dislocation of the femoral head caused an irritation and made place for excessive callus formation in the shape of the cam deformity, which damaged the cartilage and hip joint *labrum* with its presence, causing pain and limping. In this manner the femoral head kept the dislocated position.

In these malposition, the head-neck junction comes in contact with the acetabular rim of flexing the hip within normal range, especially when the leg rotated internally. The resulting sensation of pain may be caused by shear or compression of the acetabular *labrum*, which is known to carry proprioceptive and nociceptive nerve fibres similar to the knee meniscus²³.

Preoperative, subjective and objective symptoms of the patient were reduced and radiographic parameters showed, postoperatively that the values of the injured hip were brought to a level that approximated the values of the healthy hip. The reduction of alpha and gamma angles to the normal values confirms the success of the surgical procedure, i.e., it confirms the sufficient extent of osteochondroplastica. Intraoperatively, these angles can be radiologically measured and adequately corrected, without relying on uncontrolled resection that can sometimes be insufficient. The values of these angles confirm the correct anatomical relation between femoral head and neck and the absence of the cam deformity, causing the femoral neck axes p and l to overlap. Thereby, the factors of pain and further hip joint *labrum* and cartilage damage are removed.

Using this procedure we created almost normal hip anatomy. Therefore, we believe that applied surgical technique and the approach to the treatment, are of the great importance in the treatment of the trauma-induced femoroacetabular impingement in symptomatic patients with the femoral neck fractures healed in a non-anatomical position.

Conclusion

The best prevention of this form of the impingement is based on the proper and immediate surgical treatment of the

femoral neck fracture. Early surgical treatment of this form of the impingement is essential to prevent further degeneration and osteoarthritis of the hip.

R E F E R E N C E S

1. Ganz R, Parviz J, Beck M, Leunig M, Nötzli H, Siebenrock KA. Femoroacetabular impingement: a cause for osteoarthritis of the hip. *Clin Orthop Relat Res* 2003; (417): 112–20.
2. Wagner S, Hofstetter W, Chiquet M, Mainil-Varlet P, Stauffer E, Ganz R, et al. Early osteoarthritic changes of human femoral head cartilage subsequent to femoro-acetabular impingement. *Osteoarthr Cartil* 2003; 11(7): 508–18.
3. Lavigne M, Parviz J, Beck M, Siebenrock KA, Ganz R, Leunig M. Anterior femoroacetabular impingement: part I. Techniques of joint preserving surgery. *Clin Orthop Relat Res* 2004; (418): 61–6.
4. Beck M, Kalhor M, Leunig M, Ganz R. Hip morphology influences the pattern of damage to the acetabular cartilage: Femoroacetabular impingement as a cause of early osteoarthritis of the hip. *J Bone Joint Surg Br* 2005; 87(7): 1012–8.
5. Murray RO. The aetiology of primary osteoarthritis of the hip. *Br J Radiol* 1965; 38(455): 810–24.
6. Solomon L. Patterns of osteoarthritis of the hip. *J Bone Joint Surg Br* 1976; 58(2): 176–83.
7. Tönnis D, Heinecke A. Acetabular and femoral anteversion: relationship with osteoarthritis of the hip. *J Bone Joint Surg Am* 1999; 81(12): 1747–70.
8. Mladenović D, Anđelković Z, Vukasinović Z, Mitković M, Milenković S, Micić I, et al. Early clinical results of surgical treatment of patients with femoroacetabular impingement. *Srp Arh Celok Lek* 2014; 142(5–6): 325–9.
9. Mladenović M, Anđelković Z, Micić I, Mladenović D, Stojiljković P, Milenković T. Surgical dislocation of the hip in patients with femoroacetabular impingement: Surgical techniques and our experience. *Vojnosanit Pregl* 2015; 72(11): 1004–9.
10. Murphy S, Tannast M, Kim YJ, Buly R, Millis MB. Debridement of the adult hip for femoroacetabular impingement: indications and preliminary clinical results. *Clin Orthop Relat Res* 2004; (429): 178–81.
11. Mladenović M, Micić I, Anđelković Z, Mladenović D, Stojiljković P. Unusual case of mixed form of femoroacetabular impingement combined with nonspecific synovitis of the hip joint in a young adult-- A case report. *Vojnosanit Pregl* 2015; 72(12): 1132–5.
12. Stulberg SD, Cordell LD, Harris WH, Ramsey PL, MacEwen GD. Unrecognized childhood hip disease: A major cause of idiopathic osteoarthritis of the hip. In: Amstutz HC, editor. *The Hip: Proceedings of the Third Open Scientific Meeting of the Hip Society*. St Louis, MO: CV Mosby; 1975. p. 212–28.
13. Siebenrock KA, Wabab KH, Werlen S, Kalhor M, Leunig M, Ganz R. Abnormal extension of the femoral head epiphysis as a cause of cam impingement. *Clin Orthop Relat Res* 2004; (418): 54–60.
14. Goodman DA, Feighan JE, Smith AD, Latimer B, Buly RL, Cooperman DR. Subclinical slipped capital femoral epiphysis. Relationship to osteoarthrosis of the hip. *J Bone Joint Surg Am* 1997; 79(10): 1489–97.
15. Leunig M, Casillas MM, Hamlet M, Hersche O, Nötzli H, Slongo T, et al. Slipped capital femoral epiphysis: Early mechanical damage to the acetabular cartilage by a prominent femoral metaphysis. *Acta Orthop Scand* 2000; 71(4): 370–5.
16. Snow SW, Keret D, Scarangella S, Bowen JR. Anterior impingement of the femoral head: a late phenomenon of Legg-Calvé-Perthes' disease. *J Pediatr Orthop* 1993; 13(3): 286–9.
17. Vukasinović Z, Spasovski D, Živković Z. Femoroacetabular impingement related to Legg-Calvé-Perthes disease. *Srp Arh Celok Lek* 2011; 139(11–12): 834–7. (Serbian)
18. Kloen P, Leunig M, Ganz R. Early lesions of the labrum and acetabular cartilage in osteonecrosis of the femoral head. *J Bone Joint Surg Br* 2002; 84(1): 66–9.
19. Eijer H, Myers SR, Ganz R. Anterior femoroacetabular impingement after femoral neck fractures. *J Orthop Trauma* 2001; 15(7): 475–81.
20. Ganz R, Bamert P, Hausner P, Isler B, Vreiv F. Cervico-acetabular impingement after femoral neck fracture. *Unfallchirurg* 1991; 94(4): 172–5. (German)
21. McCarthy JC. The diagnosis and treatment of labral and chondral injuries. *Instr Course Lect* 2004; 53: 573–7.
22. Seldes RM, Tan V, Hunt J, Katz M, Winiarsky R, Fitzgerald RH Jr. Anatomy, histologic features, and vascularity of the adult acetabular labrum. *Clin Orthop Relat Res* 2001; (382): 232–40.
23. Kim YT, Azuma H. The nerve endings of the acetabular labrum. *Clin Orthop Relat Res* 1995; (320): 176–81.
24. Bellamy N, Buchanan WW, Goldsmith CH, Campbell J, Stitt LW. Validation study of WOMAC: a health status instrument for measuring clinically important patient relevant outcomes to antirheumatic drug therapy in patients with osteoarthritis of the hip or knee. *J Rheumatol* 1988; 15(12): 1833–40.
25. Anđelković Z, Mladenović D, Vukasinović Z, Arsić S, Mitković M, Micić I, et al. Contribution to the method for determining femoral neck axis. *Srp Arh Celok Lek* 2014; 142(3–4): 178–83.
26. Tönnis D. Normal values of the hip joint for the evaluation of X rays in children and adults. *Clin Orthop Rel Res* 1976; (119): 39–47.
27. Wiberg G. Studies on dysplastic acetabular and congenital subluxation of the hip joint. *Acta Orthop Scand* 1939; 83(Suppl 58): 7–38.
28. Nötzli HP, Wyss TF, Stoecklin CH, Schmid MR, Treiber K, Hodler J. The contour of the femoral head-neck junction as a predictor for the risk of anterior impingement. *J Bone Joint Surg Br* 2002; 84(4): 556–60.
29. Ganz R, Gill TJ, Gautier E, Ganz K, Krügel N, Berlemann U. Surgical dislocation of the adult hip a technique with full access to the femoral head and acetabulum without the risk of avascular necrosis. *J Bone Joint Surg Br* 2001; 83(8): 1119–24.
30. Gautier E, Ganz K, Krügel N, Gill T, Ganz R. Anatomy of the medial femoral circumflex artery and its surgical implications. *J Bone Joint Surg Br* 2000; 82(5): 679–83.
31. Mardones RM, Gonzalez C, Chen Q, Zobitz M, Kaufman KR, Trousdale RT. Surgical treatment of femoroacetabular impingement: Evaluation of the effect of the size of the resection. *J Bone Joint Surg Am* 2005; 87(2): 273–9.

32. Bergmann G, Deuretzbacher G, Heller M, Graichen F, Rohmann A, Strauss J, et al. Hip contact forces and gait patterns from routine activities. *J Biomech* 2001; 34(7): 859–71.
33. Malik A, Maheshwari A, Dorr LD. Impingement with total hip replacement. *J Bone Joint Surg Am* 2007; 89(8): 1832–42.
34. Leunig M, Werlen S, Ungersböck A, Ito K, Ganz R. Evaluation of the acetabular labrum by MR arthrography. *J Bone Joint Surg Br* 1997; 79(2): 230–4.

Received on October 11, 2016.
Revised on December 19, 2016.
Accepted on April 27, 2017.
Online First May, 2017.